

Hysterosalpingo-foam sonography, a less painful procedure for tubal patency testing during fertility workup compared with (serial) hysterosalpingography: a randomized controlled trial

Kim Dreyer, M.D.,^a Renée Out, M.D.,^b Peter G. A. Hompes, M.D., Ph.D.,^a and Velja Mijatovic, M.D., Ph.D.^a

^a Department of Reproductive Medicine, VU University Medical Center, Amsterdam; and ^b Department of Obstetrics and Gynecology, Spaarne Hospital, Hoofddorp, the Netherlands

Objective: To determine whether hysterosalpingo-foam sonography (HyFoSy) is a less painful first line tubal patency test than serial hysterosalpingography (HSG).

Design: A two-center, prospective, open-label, randomized, controlled trial.

Setting: University hospital and teaching hospital.

Patient(s): 40 subfertile women, ages 18 to 41 years, with an indication for tubal patency testing as part of the fertility workup according to the Dutch Nederlandse Vereniging voor Obstetrie & Gynaecologie-guidelines.

Intervention(s): Tubal patency testing by HyFoSy versus serial HSG.

Main Outcome Measure(s): Visual Analogue Scale (VAS) pain scores during tubal patency testing.

Result(s): The median VAS score for pain perception during the HyFoSy procedure was 1.7 cm (interquartile range: 2.1) compared with 3.7 cm (interquartile range: 4.2) during HSG. The HyFoSy procedure also had a statistically significantly shorter procedure time compared with HSG, with a median of 5.0 minutes (interquartile range: 3.0) for HyFoSy versus 12.5 minutes (interquartile range: 16.0) for HSG.

Conclusion(s): The HyFoSy procedure is a less painful and less time-consuming tubal patency test compared with HSG.

Clinical Trial Registration Number: Netherlands National Trial Register NTR3457. (Fertil Steril® 2014;102:821–5. ©2014 by American Society for Reproductive Medicine.)

Key Words: HSG, HyFoSy, hysterosalpingo-foam sonography, hysterosalpingography, pain perception, tubal patency test, subfertility

Discuss: You can discuss this article with its authors and with other ASRM members at <http://fertstertforum.com/dreyer-k-hyfosy-tubal-patency-testing-serial-hysterosalpingography/>



Use your smartphone to scan this QR code and connect to the discussion forum for this article now.*

* Download a free QR code scanner by searching for "QR scanner" in your smartphone's app store or app marketplace.

The rate of subfertility, defined as the inability to conceive within 12 months of unprotected intercourse, has been slowly increasing in

recent years (1). More women postponing the initiation of a family until later in life and an increase in the incidence of pelvic inflammatory disease

have been suggested as causes. Subfertility affects approximately one in six couples attempting to achieve pregnancy (2, 3). In the Netherlands, approximately 30,000 couples consult a gynecologist for subfertility each year (3).

Traditionally, the diagnostic workup for subfertility includes an ovarian reserve test, assessment of the (ovulatory) cycle, semen analysis, and a tubal patency test, with hysterosalpingography (HSG) and diagnostic laparoscopy (DLS) as the most established patency tests (4). Diagnostic laparoscopy enables

Received April 9, 2014; revised May 20, 2014; accepted May 27, 2014; published online July 1, 2014. K.D. has nothing to disclose. R.O. has nothing to disclose. P.G.A.H. has received grant support from Ferring B.V., Merck B.V., Abbott B.V., and Conceptus Inc. V.M. has nothing to disclose.

Supported by IQ Medical Ventures BV, Delft, the Netherlands. The funders had no role in study design, data collection and analyses, decision to publish, or preparation of the manuscript.

Reprint requests: Kim Dreyer, M.D., Department of Reproductive Medicine, VU University Medical Center, Policlinic 6Z, Room 180, P.O. Box 7057, 1007 MB, Amsterdam, the Netherlands (E-mail: k.dreyer@vumc.nl).

Fertility and Sterility® Vol. 102, No. 3, September 2014 0015-0282/\$36.00
Copyright ©2014 American Society for Reproductive Medicine, Published by Elsevier Inc.
<http://dx.doi.org/10.1016/j.fertnstert.2014.05.042>

direct visualization of the pelvis, including the fallopian tubes, ovaries, and uterus, but it is an invasive test that requires general anesthesia. Hysterosalpingography is a minimally invasive test that can be performed on an outpatient basis, so it is still the test of first choice during the fertility workup in many clinics in the Netherlands. However, most women experience moderate to severe pain during this procedure (5).

Since 1986, hysterosalpingo-contrast sonography (HyCoSy) has been proposed as a less invasive alternative for HSG and DLS as a first-line tubal patency test. The accuracy of HyCoSy is comparable to or even better than that of HSG in predicting tubal patency (6–9). However, the required echogenic medium for HyCoSy, Echovist gel, is no longer available.

By replacing Echovist gel by foam, the hysterosalpingo-foam sonography (HyFoSy) procedure was introduced in 2011 as a new technique for tubal patency testing (10). HyFoSy is supposed to be as accurate as HyCoSy and thus as accurate as HSG in predicting tubal patency (11). The advantages of HyFoSy over laparoscopy include that HyFoSy does not require general anesthesia and has no risk of visceral damage or intra-abdominal bleeding. On the other hand, HyFoSy does not provide information about the pelvic anatomy or the possibility of ovum pickup, which DLS does. Compared with HSG, HyFoSy does not show the mucosal folds of the ampules. However, HyFoSy does not only provide information about the patency of the fallopian tubes, it also allows the ovaries to be assessed at the same time. Furthermore, HyFoSy does not involve radiation exposure, which makes it a more patient friendly and less expensive examination compared with HSG. In addition, HyFoSy can be performed by the gynecologist during regular office hours, so the fertility workup can be accomplished as a single clinical evaluation.

Another perceived advantage of HyFoSy is that it might be a less painful procedure than HSG for tubal patency testing. Our clinical trial investigated whether HyFoSy is indeed a less painful procedure than HSG as a first-line tubal patency test during the fertility workup.

MATERIALS AND METHODS

We conducted a two-center, prospective, open-label, randomized, controlled trial to compare tubal patency testing using HyFoSy and HSG. We randomized participants to HyFoSy or HSG by use of a computer-generated randomization list when a tubal patency test was planned. Our primary outcome was pain experienced during the procedure as measured by visual analogue scale (VAS) scores (1.0–10.0 cm) obtained immediately after the examination. Our secondary outcomes were procedure time and amount of contrast medium needed.

We recruited participants in the VU University Medical Center, Amsterdam, and Spaarne Hospital, Hoofddorp, the Netherlands. We included women aged between 18 and 41 years who had a valid indication for tubal patency testing as part of their fertility workup according to the Dutch NVOG guidelines (4). We excluded women with a high risk for tubal pathology (such as women with a history of *Chlamydia* infection, pelvic inflammatory disease, or peritonitis) because these conditions might be associated with higher pain scores

during HSG (5). We also excluded women with a known allergy to iodine and those who were not willing or able to provide written informed consent. The study was approved by the institutional review board of the VU University Medical Center, and all participants gave informed consent.

Clinical Methods

No form of premedication was given before tubal patency testing. Both tests were performed after complete cessation of menstrual bleeding and before the 14th day in the ovulatory cycle. Patients were placed in a supine position. A vaginal speculum by Trelat was inserted, and the cervix was cleaned with povidone-iodine.

Hysterosalpingographies were performed using a hystero-phore, with just one tenaculum on the cervix anterior lip, to infuse approximately 10 cc of contrast medium into the uterine cavity and fallopian tubes. Two contrast media (Telebrix Hystero in the VU University Medical Center, or Lipiodol Ultra Fluid in the Spaarne Hospital; Guerbet, Netherlands B.V.) were used to perform the HSGs. Instillation of the contrast medium was done at a velocity of 100 cc per hour by an instillation pump according to our local protocol (Pilot Anesthesie; Fresenius Vial S.A.). During instillation of the contrast medium, six to eight X-rays (AXIOM Iconos R 200; Siemens) were made to assess the uterine cavity and to see whether the fallopian tubes were patent.

For HyFoSy, we placed a small cervical balloon-less catheter through which we infused approximately 10 cc of foam into the uterine cavity. This foam was created by rigorously mixing 10 cc ExEm-gel (IQ Medical Ventures BV) with 10 cc of purified water in a 20-cc syringe (10). Instillation of the foam was also performed at a velocity of 100 cc per hour by an instillation pump (Pilot Anesthesie). During instillation of the foam, a transvaginal ultrasound (EnVisor; Philips) was performed by the gynecologist. During the ultrasound, we screened for intracavitary pathology and assessed the patency of the fallopian tubes.

Sample Size Calculation and Statistical Analyses

To calculate the required sample size, we assumed a mean VAS of 2.0 cm for pain experienced during HyFoSy and a mean VAS of 4.0 cm during HSG, with a standard error of 2.0 cm in both groups and the use of a two-sided, two-sample equal-variance *t* test with a statistical significance level of .05 (12). Including 17 women in the HyFoSy and 17 women in the HSG group would give us 80% power to reject the null hypothesis of an equal mean VAS for pain experienced during HyFoSy and HSG. We anticipated that 15% of the women would drop out of the study, so we included 20 women in each group. We analyzed the data according to the intention-to-treat principle.

Differences in outcomes of continuous data (VAS pain scores, procedure time, and amount of contrast medium needed) were tested for statistical significance using a Mann-Whitney *U* test. These data are presented with a median and interquartile range (IQR). Differences in categorical data were tested for statistical significance using a Fisher exact test or a Fisher-Freeman-Halton test.

RESULTS

The required 40 women (20 women in the VU University Medical Center and 20 women in the Spaarne Hospital) were enrolled between January 2013 and September 2013. There were no differences in the patient characteristics among the women who underwent a HyFoSy procedure and those who underwent a HSG (see Table 1).

Our primary outcome, the VAS pain scores, were statistically significantly lower for the HyFoSy procedures (median 1.7 cm IQR 2.1) compared with HSG (median 3.7 cm IQR 4.2) ($P < .01$). Our secondary outcome, procedure time, was statistically significantly shorter for HyFoSy (median 5.0 min IQR 3.0) compared with HSG (median 12.5 min IQR 16.0) ($P < .01$). There was no difference in the amount of used contrast medium between HyFoSy and HSG. Among the women randomized for HyFoSy and HSG, there were no differences in diagnoses and prognoses after completion of the fertility workup. (see Table 2).

In one patient, randomized for HSG, a balloon catheter was used instead of a hysteroscope because of the inability to infuse enough contrast medium into the uterine cavity through the hysteroscope. For HyFoSy, we needed to use a tenaculum in two patients to introduce the balloon-less

catheter into the cervical canal. In two patients, filling of the fallopian tubes during HSG was insufficient during the slow infusion of the contrast medium by the instillation pump, so we had to purge the contrast medium by hand. For the same reason, we had to purge the medium in another patient randomized for HyFoSy. Two of the 20 women randomized for HyFoSy needed a subsequent HSG because of an inconclusive assessment of tubal patency using the HyFoSy procedure. (see Fig. 1). In one of these women, we could not get enough intrauterine pressure because of cervical leakage, so we could not assess the patency of her left tube; a subsequent HSG was needed to confirm the patency of her left tube. In the other woman, filling of both fallopian tubes could not be achieved during HyFoSy, so a subsequent HSG was needed to visualize bilateral patent tubes. None of the 20 women randomized for a serial HSG needed a subsequent HyFoSy procedure. There occurred no complications (bleeding or infection after tubal patency test) in either study groups.

DISCUSSION

This is the first prospective, randomized, controlled trial to evaluate pain scores between the recently introduced ultrasonographic first-line tubal patency test HyFoSy and HSG. Our trial shows a statistically significantly lower median VAS pain score in favor of the HyFoSy procedure (1.7 cm versus 3.7 cm; $P < .01$). Furthermore, the procedure time for HyFoSy is statistically significantly shorter than for HSG (median 5.0 minutes versus 12.5 minutes; $P < .01$).

Our findings are in line with the results of our previous study, in which we compared the VAS pain scores between a HyFoSy procedure and HSG in women with proximal occluded tubes. That study showed a 75% lower VAS pain score during the HyFoSy procedure (1.5 cm versus 4.3 cm for HyFoSy and HSG, respectively) (12).

During HSG, a hysteroscope (metal cannula) as well as a balloon catheter can be used to infuse the contrast medium into the uterine cavity. A disadvantage of a balloon catheter is the possibility the balloon does not remain in the cervical canal during HSG. In that case, a metal cannula needs to be used during a second attempt. Another disadvantage of a balloon catheter, when it has an intrauterine placement, is the inability to adequately evaluate the uterine cavity. Because of the lack of evidence that a balloon catheter during HSG is less painful in combination with the aforementioned disadvantages, we chose to use the hysteroscope (metal cannula) to perform the HSGs during this study (15).

For HSG, we used two different contrast media during this study according to the local protocol of both participating clinics (Telebrix Hystero and Lipiodol Ultra Fluid; Guerbet, Netherlands B.V.). Lindequist et al. (16) showed no difference in pain perception between the use of water- or oil-based contrast medium during HSG. An analysis of our results showed no difference in VAS pain scores during HSG between both clinics ($P = .44$), confirming this result.

Limitations

This study was not blinded, which may introduce bias. Because of the difference in the nature of both tests

TABLE 1

Patient characteristics.			
Characteristic	HyFoSy (n = 19)	HSG (n = 20)	P value
Age (y)	33.0 (IQR 6.0)	31.5 (IQR 10.0)	.49 ^a
BMI (kg/m ²)	20.8 (IQR 4.6) ^b	21.7 (IQR 6.2) ^c	.47 ^a
Duration of subfertility (mo)	15.1 (IQR 9.9)	15.2 (IQR 6.8)	.81 ^a
Subfertility type			.16 ^d
Primary subfertility	12/19	17/20	
Secondary subfertility	7/19	3/20	
FSH (U/L)	6.0 (IQR 2.3) ^e	6.2 (IQR 3.2) ^f	.30 ^a
Referral			.80 ^g
General practitioner	16/19	18/20	
Other gynecologist	2/19	1/20	
Own initiative	1/19	1/20	
Medical history			1.00 ^g
None	14/19	14/20	
Gastrointestinal	1/19	2/20	
Gynecology	2/19	3/20	
Dermatological deviations	1/19	0/20	
Other	1/19	1/20	
Ethnicity			1.00 ^g
Caucasian	16/19	17/20	
Indian/Pakistan/ Bangladesh	1/19	1/20	
Middle-Eastern/ North-African	1/19	2/20	
Asian	1/19	0/20	
ART in history			.23 ^g
None	17/19	20/20	
IUI	2/19	0/20	

Note: BMI = body mass index; HSG = hysterosalpingography; HyFoSy = hysterosalpingo-foam; IQR = interquartile range; IUI = intrauterine insemination.

^a Mann-Whitney U test.

^b Based on 15 patients.

^c Based on 16 patients.

^d Fisher's exact test.

^e Based on 13 patients.

^f Based on 12 patients.

^g Fisher-Freeman-Halton test.

Dreyer. VAS study. *Fertil Steril* 2014.

TABLE 2

Primary and secondary outcomes.	HyFoSy (n = 19)	HSG (n = 20)	P value
Primary outcome			
VAS pain score (cm)	1.7 (IQR 2.1)	3.7 (IQR 4.2)	< .01 ^a
Secondary outcomes			
Procedure time (min)	5.0 (IQR 3.0) ^b	12.5 (IQR 16.0)	< .01 ^a
Volume of infused contrast medium (mL)	5.8 (IQR 4.6)	8.3 (IQR 7.8)	.10 ^a
Conclusion after TT			1.00 ^c
Both tubes patent	17/19	17/20	
Unilateral proximal occlusion	2/19	1/20	
Bilateral proximal occlusion	0/19	1/20	
Other	0/19	1/20	
Diagnosis			1.00 ^c
Idiopathic	11/18	12/19	
Tubal pathology	2/18	2/19	
Mild male factor	4/18	3/19	
Oligo-/amenorrhoea	1/18	1/19	
Other	0/18	1/19	
Prognostic chance on natural conception during the following 12 months (%) (13, 14)	34.3 (IQR 18.8) ^d	32.3 (IQR 19.2) ^e	.60 ^a

Note: HSG = hysterosalpingography; HyFoSy = hysterosalpingo-foam; IQR = interquartile range; VAS = visual analog scale.
^a Mann-Whitney *U* test.
^b Based on 18 patients.
^c Fisher-Freeman-Halton test.
^d Based on 16 patients.
^e Based on 12 patients.

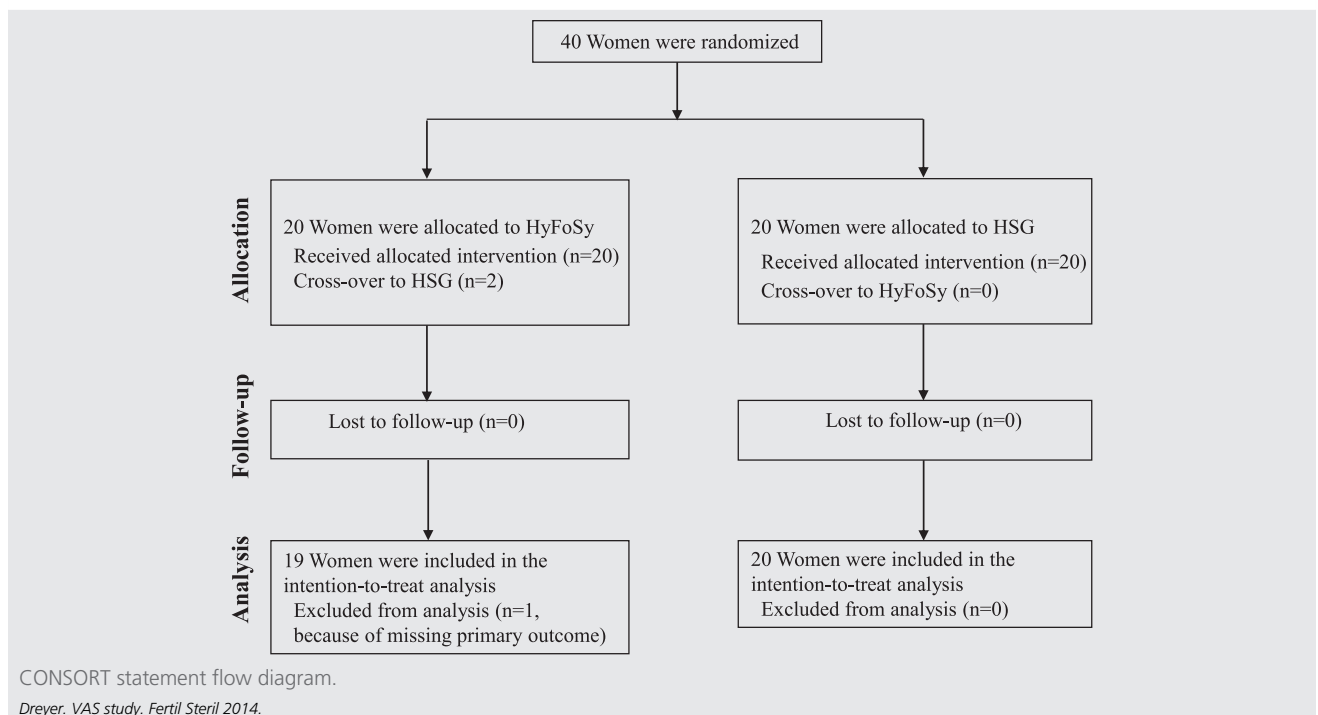
Dreyer. VAS study. *Fertil Steril* 2014.

(ultrasound versus radiologic procedure), it would have been difficult and not feasible to blind the patients and gynecologist during this study. To reduce this bias as much as possible, we counseled the patients eligible for participation in a standardized manner. They were told that different aspects (such as procedure time, amount of contrast needed, ability to

show tubal patency, and pain scores) of a new tubal patency test would be compared with the current most widely used, first-line tubal patency test. The patients were not informed about our hypothesis that HyFoSy might be less painful.

Although there have been no randomized trials evaluating the accuracy of tubal patency testing by HyFoSy

FIGURE 1



compared with HSG or with the gold standard (laparoscopic chromopertubation), HyFoSy is assumed to be as accurate as HyCoSy and hence as HSG. This is supported by the results of two prospective observational studies. Schoubroeck et al. (17) studied 20 consecutive subfertile women who were scheduled for laparoscopic chromopertubation. All 20 women underwent a HyFoSy procedure just before laparoscopy. The results showed a 100% agreement between tubal patency data according to HyFoSy testing and laparoscopic chromopertubation testing. Furthermore, Emanuel et al. (11) showed in their prospective observational cohort study that HyFoSy was a successful first line test to demonstrate tubal patency. In this study, 73 subfertile women underwent a HyFoSy procedure as first-line tubal patency test. In 16 patients (22%), a subsequent HSG was required because of an inconclusive result during HyFoSy. The investigators concluded that using HyFoSy for tubal patency testing could avoid a HSG in about 78% of subfertility cases (11).

Wider Implications

In the current trial, there were only two patients who needed a subsequent HSG after HyFoSy because of inconclusive results. This finding suggests that in case a HyFoSy procedure is performed as the first-line tubal patency test during the fertility workup, a HSG can be avoided in the vast majority of cases. In addition to the previously stated advantages of HyFoSy, the procedure appears to be less expensive than HSG. Using the crude price estimates in the Netherlands, the average cost of a HSG examination is 170 Euros compared with approximately 70 Euros for a single HyFoSy procedure.

In general, HyFoSy is a less painful and less time-consuming tubal patency test compared to HSG. It also appears to be an accurate and safe test that can be performed by a single operator in an outpatient clinic setting without the need for radiation exposure, making it a far more patient-friendly first-line tubal patency test. Future research should focus on whether tubal patency testing during the fertility workup using HyFoSy leads to the same diagnostic outcomes, subsequent management decisions, and ongoing pregnancy rates as tubal testing using HSG.

Acknowledgments: The authors thank Mandy Griffioen and Jaqueline Sanders for their excellent logistical assistance in this study, Rebecca Holman for checking the statistical analyses, and Mark Hans Emanuel for performing the HyFoSy procedures in Spaarne Hospital.

REFERENCES

1. Silverberg KM. Evaluation of the couple with infertility in a managed care environment. *Clin Obstet Gynecol* 2000;43:844–53.
2. Hull MG, Glazener CM, Kelly NJ, Conway DI, Foster PA, Hinton RA, et al. Population study of causes, treatment, and outcome of infertility. *Br Med J (Clin Res Ed)* 1985;291:1693–7.
3. Beurskens MP, Maas JW, Evers JL. Subfertility in South Limburg: calculation of incidence and appeal for specialist care. *Ned Tijdschr Geneesk* 1995;139:235–8.
4. NVOG guidelines. National guidelines for subfertility. Dutch guidelines for Obstetrics and Gynaecology, 2010.
5. Chauhan MB, Lakra P, Jyotsna D, Nanda S, Malhotra V. Pain relief during hysterosalpingography: role of intracervical block. *Arch Gynecol Obstet* 2013;287:155–9.
6. Reis MM, Soares SR, Cancado ML, Camargos AF. Hysterosalpingo contrast sonography (HyCoSy) with SH U 454 (Echovist) for the assessment of tubal patency. *Hum Reprod* 1998;13:3049–52.
7. Dijkman AB, Mol BW, van der Veen F, Bossuyt PM, Hogerzeil HV. Can hysterosalpingocontrast-sonography replace hysterosalpingography in the assessment of tubal subfertility? *Eur J Radiol* 2000;35:44–8.
8. Saunders RD, Shwayder JM, Nakajima ST. Current methods of tubal patency assessment. *Fertil Steril* 2011;95:2171–9.
9. Lim CP, Hasafa Z, Bhattacharya S, Maheshwari A. Should a hysterosalpingogram be a first-line investigation to diagnose female tubal subfertility in the modern subfertility workup? *Hum Reprod* 2011;26:967–71.
10. Emanuel MH, Exalto N. Hysterosalpingo-foam sonography (HyFoSy): a new technique to visualize tubal patency. *Ultrasound Obstet Gynecol* 2011;37:498–9.
11. Emanuel MH, van Vliet M, Weber M, Exalto N. First experiences with hysterosalpingo-foam sonography (HyFoSy) for office tubal patency testing. *Hum Reprod* 2012;27:114–7.
12. Dreyer K, Mijatovic V, Emanuel MH, Hompes PGA. Hysterosalpingo-foam sonography (HyFoSy), a new technique to confirm proximal tubal occlusion after treatment of a hydrosalpinx by an Essure device prior to in vitro fertilization (IVF). *Fertil Steril* 2012;98(Suppl):S224.
13. Hunault CC, Habbema JD, Eijkemans MJ, Collins JA, Evers JL, te Velde ER. Two new prediction rules for spontaneous pregnancy leading to live birth among subfertile couples, based on the synthesis of three previous models. *Hum Reprod* 2004;19:2019–26.
14. van der Steeg JW, Steures P, Eijkemans MJ, Habbema JD, Hompes PG, Broekmans FJ, et al, CECERM study group. Pregnancy is predictable: a large-scale prospective external validation of the prediction of spontaneous pregnancy in subfertile couples. *Hum Reprod* 2007;22:536–42.
15. Stoop D, De Brucker M, Haentjens P, Talebian A, de Mey J, Devroey P. Fast-release orodispersible tramadol as analgesia in hysterosalpingography with a metal cannula or a balloon catheter. *Hum Reprod* 2010;25:1451–7.
16. Lindequist S, Rasmussen F, Larsen C. Use of iotrolan versus ethiodized poppy-seed oil in hysterosalpingography. *Radiology* 1994;191:513–7.
17. Van Schoubroeck D, Van den Bosch T, Meuleman C, Tomassetti C, D'Hooghe T, Timmerman D. The use of a new gel foam for the evaluation of tubal patency. *Gynecol Obstet Invest* 2013;75:152–6.